

## REVIEW

# Identifying the right patient for iliofemoral venous stenting

Efthymios D. Avgerinos, MD

Division of Vascular Surgery, University of Pittsburgh Medical Center, Pittsburgh, USA

**Abstract:**

Venous iliofemoral and caval stenting are increasingly used as more evidence accumulates supporting the open vein hypothesis, the safety, efficacy, and durability of these interventions. The indications are still evolving, but there is little doubt that certain patients with iliofemoral venous occlusive disease, acute or chronic, can avoid or abolish pain, swelling and chronic non-healing ulcers to enjoy a better quality of life. Knowing the right indications, following standardized protocols and technical steps are all critical components of a successful outcome and vascular surgeons will be increasingly asked to get involved.

**Keywords**

Deep vein thrombosis, chronic venous insufficiency, venous stenting, post-thrombotic syndrome, iliac vein compression

**INTRODUCTION**

Ilio-femoral venous obstruction is a common condition that may have been underestimated as a major cause of disability and has been traditionally managed conservatively. Venous obstruction can occur because of extrinsic compression (malignancy or anatomic variants), because of acute or chronic deep vein thrombosis (DVT).<sup>1-3</sup> Patient symptoms are variable and largely dependent on the cause, extent of venous obstruction, and disease duration.<sup>1-3</sup>

While for the majority of iliofemoral occlusive venous disease cases compression and/or anticoagulation may be optimal, certain patients will have symptoms that interfere with their quality of life. These patients may benefit from catheter-based therapies and iliofemoral stenting, a growing field that vascular surgeons will be increasingly asked to get involved. During the last decade, the endovascular management of iliofemoral or ilio-caval obstruction has superseded open venous reconstructions. The safety, efficacy and durability of indicated endovascular interventions for ilio-caval obstruction have been extensively demonstrated.<sup>2,3</sup> Knowing the right indications, following standardized protocols and technical steps are all critical components of a successful outcome.<sup>1-5</sup>

**Extrinsic Iliac Vein Compression**

Iliac vein compression syndrome (IVCS), also called May-Thurner or Cockett syndrome is an anatomic variant manifesting

with symptoms of chronic venous insufficiency, mainly lower extremity swelling, pain, varicosities and in its extreme form acute DVT. In its most frequent anatomic pattern there is compression of the left common iliac vein against the lumbar spine by the overlying right common iliac artery, but right sided syndrome can also occur. The traditional nomenclature may be confusing so the term nonthrombotic iliac vein lesion (NIVL) has been suggested.<sup>6</sup> Anatomic studies in cadavers and CT imaging reviews of asymptomatic patients indicate that ~25% have an at least 50% stenosis of the left common iliac vein by the overlying right iliac artery.<sup>7,8</sup>

Despite its high incidence in the general population, NIVL remains largely silent and we do not really know why not everybody develops symptoms. It is believed that NIVLs are permissive lesions meaning that additional pathologies such as trauma, cellulitis, distal thrombosis, lymphatic exhaustion, or reflux will trigger the symptoms.<sup>6</sup> The typical symptomatic patient is a young woman 20-40 years old. The rationale for treatment in these young female patients is to offer relief from swelling, venous claudication, varices (leg and pubis) and why not for cosmesis. Iliac vein stenting can abolish external compression, provide venous outflow and symptom relief.

In 2003, the Raju group demonstrated that 50% of patients with pain and 55% with venous ulceration reported improvement following stent placement in NIVL.<sup>9</sup> In 2006, the same group reported a cohort of 316 patients treated for NIVL of which 82% and 77% with and without venous reflux, respectively, reported resolution of their lower-extremity edema.<sup>6</sup> In the largest systematic review to date, iliac vein stenting for NIVL provided the best outcomes against any other indication for stenting (acute or chronic DVT): 5 year primary and secondary patency 90% and 98% respectively.<sup>2</sup> Based on such robust evidence, in today's practice iliac vein stenting is the standard of care for symptomatic NIVL and this has been reflected in the most recent European Society for Vascular Surgery guidelines (Class IIa, Level B).<sup>10</sup>

**Author for correspondence:**

**Efthymios D. Avgerinos, MD**

Associate Professor of Surgery

Heart and Vascular Institute, South Tower, Building 3, Office 351.1 Presbyterian University Hospital, 200 Lothrop St, Pittsburgh, PA 15213

E-mail: avgerinose@upmc.edu,

Tel.: (412)8023032, (412)8023036

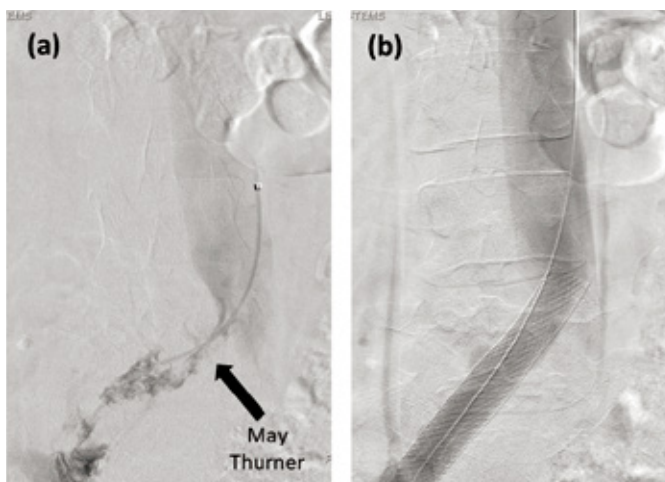
ISSN 1106-7237/ 2019 Hellenic Society of Vascular and Endovascular Surgery Published by Rotonda Publications All rights reserved. <https://www.heljves.com>

### Acute DVT

Catheter-directed thrombolysis (CDT) for acute iliofemoral deep venous thrombosis (DVT) has been increasingly used over the past decade targeting severe acute symptomatology and potentially prevention of post-thrombotic syndrome (PTS). The results of various retrospective and prospective randomized studies have been inconsistent, but there is little doubt that CDT will remain in the treatment armamentarium for patients with symptomatic iliofemoral DVT with good life expectancy and low bleeding risk.<sup>11-15</sup>

The long-anticipated results of the ATTRACT trial have challenged the expectations of CDT believers, demonstrating a relatively high post-thrombotic rate irrespective of treatment modality (47% for CDT vs 48% for anticoagulation (AC) at 2 years,  $P=.56$ ).<sup>16</sup> In addition to the invasive nature of CDT, higher (though still low (1.7%)) major bleeding complications were seen. However, CDT reduced early DVT symptoms and the severity of post-thrombotic syndrome (PTS). While the study is unique and sets the benchmark for the treatment of acute iliofemoral DVT, there should be caution in the interpretation as selection bias and dilution of the sample with softly indicated cases (e.g. femoropopliteal DVTs may have skewed the results).<sup>17</sup> The significant reduction of PTS severity with CDT should not be underestimated (risk ratio, 0.73; 95% CI, 0.54 to 0.98;  $P = 0.04$ ). PTS was defined as Villalta score  $>4$ . As such, patients with mild symptoms (itching, mild edema etc.) were as frequent in the CDT group as in the AC group. When assessing an invasive vs. a non-invasive DVT treatment, moderate to severe PTS might have been a more appropriate primary endpoint.

The main advantages of catheter-based interventions are re-establishment of iliofemoral inline flow, faster symptom resolution, valve function preservation and reduction of PTS severity. Interventional success rates are high, with reported 2 and 5-year patency rates between 65-90%.<sup>5, 14, 18-22</sup> Stenting of iliac vein narrowing or obstruction noted to be present following thrombolysis seems to be a critically important component of a successful procedure.<sup>5, 12</sup> (Figure 1) This is currently recommended by both the American Venous Forum (Grade 1, Level C) and CIRSE (no Grade or level of evidence reported) guidelines.<sup>23, 24</sup>



**Figure 1.** 28 year old female with acute left iliofemoral deep vein thrombosis undergoing thrombolysis (patient is in prone position). (a) notice the thrombus and the tight common iliac vein compression/stenosis; (b) final result after completion of thrombolysis and iliac vein stenting with a 16mm Wallstent (Boston Scientific, Nantick, MA) extending into the inferior vena cava.

### Chronic DVT

The PTS represents the constellation of symptoms seen with chronic venous disease (CVD) and is regarded as the single most common DVT complication occurring in 20% to 50% of cases.<sup>25</sup>

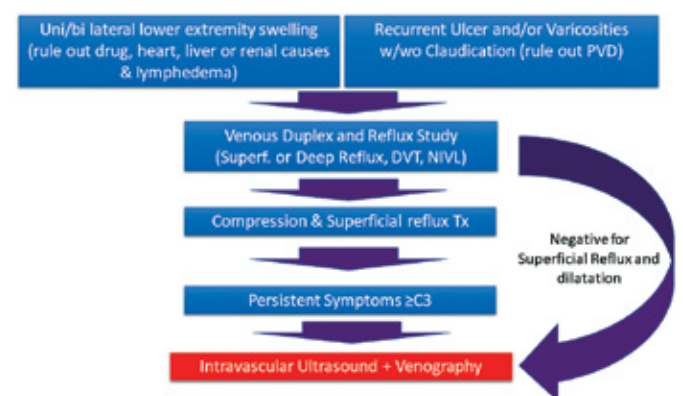
The diagnosis of PTS is predominantly supported by clinical signs (pain on calf compression, skin edema, induration, pigmentation, erythema, venous ectasia, and ulcers) and clinical symptoms (leg pain, cramps, heaviness, paresthesia, and itching). Initial conservative management of CVD includes lifestyle modifications (moderate physical activity and leg elevation), compression therapy, and pharmacologic therapy. When these fail interventional options may be beneficial.<sup>10, 23, 24</sup>

Venous reflux but not obstruction, has been the “central theme in CVD” for the last half century. However, the advances in diagnosis and imaging techniques, mainly the intravascular ultrasound scan (IVUS), have allowed us to better understand the obstructive pathophysiology of venous disease. Although the combination of obstruction and deep reflux is present in most CVD, the Raju group demonstrated that resolving the obstructive pathologic condition alone (through stenting) among patients with deep venous system reflux offered complete or partial pain relief (78% at 5 years).<sup>26</sup> The anticipated primary and secondary stent patency at 5 years should be anticipated to exceed 60% and 85%.<sup>2</sup>

As such, stent treatment has been recommended for patients with CEAP (clinical, etiology, anatomic, pathophysiology) IV-VI and occlusive iliac venous disease,<sup>27</sup> yet the guidelines’ recommendation is weak.<sup>10, 24</sup> Level one evidence will be available once the C-TRACT trial is complete. C-TRACT is an NIH-funded trial: 374 subjects with established PTS will be randomized in a 1:1 ratio to either endovascular therapy (plus optimal compression) or optimal compression only. Subjects are currently enrolling in 20-40 U.S. centers and will be followed for 24 months.

### Identifying the right patient for venous stenting

Identifying the right candidate for venous stenting is founded within the basics of an appropriate medical history and physical exam. (Figure 2)



**Figure 2.** Clinical algorithm to identify and patients who might benefit from iliac vein stenting

PVD: Peripheral vascular diseases; DVT: Deep vein thrombosis, NIVL: Non thrombotic iliac vein lesion

The acute DVT patient will typically have more intense recent onset symptomatology while the chronic DVT or NIVL

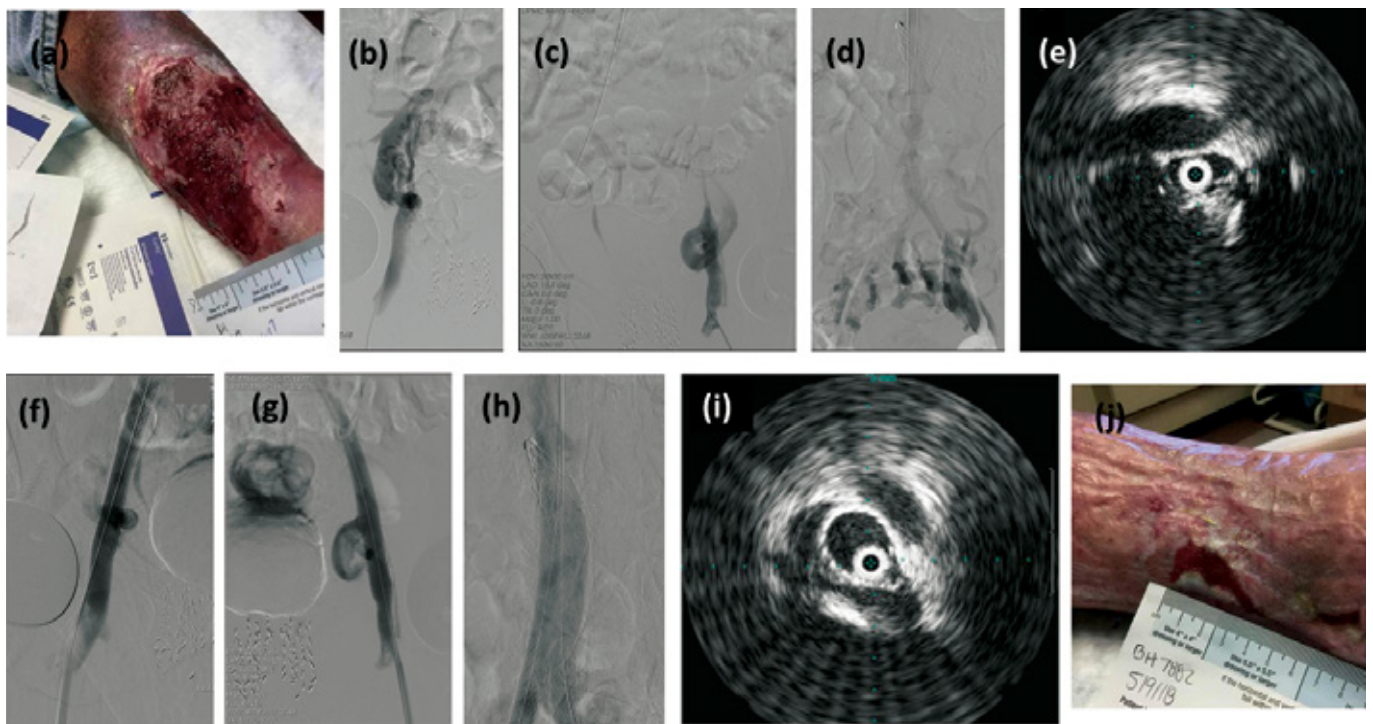
patients will report long lasting symptoms. The patient whom we should suspect having iliac occlusive disease should be one complaining of leg swelling and/or pain, manifesting early or late signs of chronic venous insufficiency (skin discoloration, varicosities or non-healing ulcers). Symptomatology at the thighs should raise suspicion of iliac venous disease. Physical exam beyond the legs should always include inspection of the pubic area, pelvis and abdomen for enlarged veins that will indicate underlying central venous occlusion. If no prior DVT is clearly known, careful history taking will reveal an old event that might have involved a silent DVT (e.g. major surgery or trauma, temporary swelling or pain, cellulitis etc). Unilateral edema alone should of course include a differential diagnosis of lymphedema and associated pathologies (e.g. abdominal malignancy). Bilateral edema should raise concerns for heart, liver or renal causes and drug induced edema (e.g calcium channel blockers), but IVC occlusion should remain as a possible diagnosis. Presence of an ulcer should also include ruling out peripheral arterial disease. Classification per the CEAP (Clinical presentation, Etiologic factors, Anatomic location, Pathologic process) system and venous clinical severity or Villalta scoring will help in classify chronic venous disease and guide the pretreatment and post-treatment assessments.<sup>28-30</sup>

Venous duplex ultrasound should be the first imaging study; it is easy to obtain, cheap and reliable in the hands of appropriate operators. Venous duplex will offer information on superficial or deep reflux, acute or chronic DVT and on non-thrombotic obstructing iliac vein lesions. The criteria for the diagnosis of iliac vein stenosis or occlusion include: loss of phasicity in the contralateral common femoral vein and/or

contralateral asymmetry, mosaic color at the exit of the stenosis, poor flow augmentation, low amplitude signals and peak vein velocity ratio (post/pre stenotic)  $>2.5$ .<sup>31</sup>

If superficial reflux with dilatation is identified, its treatment (ablation) should be prioritized as it is much simpler, cheaper, low risk and can be at least partially efficient in symptom resolution and ulcer healing in patients with combined superficial and deep vein reflux.<sup>26, 32-34</sup> Significant leg swelling, pain disproportionate to the superficial reflux, presence of deep reflux only or persistent ulcer despite endovenous ablation are good indicators to pursue intravascular ultrasound and consider iliac vein stenting. At all times, implementation of appropriate compression is of outmost importance.

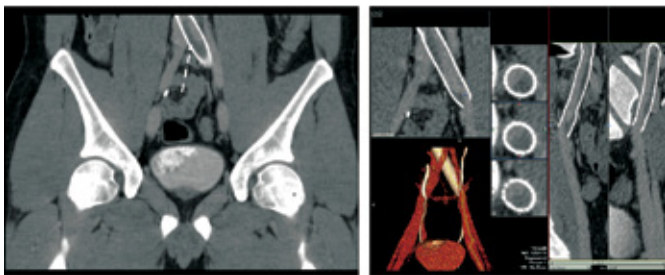
The decision to proceed to further assessment or interventional management of central vein obstructive lesions, has to be rationalized based on the patient's age and life expectancy, level of activity and degree of disability (physical or emotional) his or her symptoms cause. As a general rule young, active good risk patients will benefit the most from iliac vein stenting (along with thrombolysis for those with acute DVT). Still, older good risk patients with chronic non-healing leg wounds that do not respond to compression will likely benefit by their tremendous improvement in their quality of life. (Figure 3) The rational for iliac vein stenting is not much different from the rational of treating peripheral vascular disease in claudicants: it's about quality of life. Alongside, a failed venous intervention (e.g. stent rethrombosis) will most likely be benign compared to a failed arterial intervention that may lead to critical limb ischemia.



**Figure 3.** 78 year old male with chronic non healing left leg ulcer (a), known history of DVT and filter placement 10 years ago. (b), (c) right and left femoral vein access, multiple collaterals and occluded right and left iliac vein; (d) bilateral iliac vein occlusions have been crossed, notice there is caval disease up to the level of the filter; (e) intravascular ultrasound, right common iliac vein almost completely collapsed around the IVUS catheter; (f) (g) (h) right and left iliac veins stented down to the level of the inguinal ligaments and proximal to the level of the filter; (i) widely patent right common iliac vein stent; (j) ulcer status 6-months after the procedure



For those patients whose symptoms persist despite appropriate compression and/or superficial reflux elimination, and we have decided that they might benefit from iliac stenting, further assessment with venography and intravascular ultrasound is required. Preoperative CT or MR venogram can have a role for patients who are anticipated to have complex lesions for better planning, for patients whom we are unsure if they have any lesion at all (e.g. obese patients, poor ultrasound quality).<sup>35-37</sup> CT and MR venogram can accurately identify external arterial compression and also exclude extravascular disease causing obstruction, such as neoplasms or retroperitoneal fibrosis. Still, there is insufficient scientific evidence to adequately judge the true effectiveness of both techniques for visualization of the venous vasculature. The decision of whether to perform MRV or CTV is mainly dependent on the local expertise. (Figure 4)



**Figure 4.** CT venography in a patient with recurrent left leg swelling a year after left common iliac vein stenting for May Thurner Syndrome. Notice the subocclusive thrombus within the stent. Venous Duplex was inconclusive.

In our practice, CTV or MRV will only be obtained selectively (uncertainty for the pathology, anticipated complex case), as ascending phlebography can be used both for diagnostic and therapeutic purposes. Intravascular ultrasound is otherwise emerging as the gold standard for the diagnosis of vein stenosis as it was recently shown that it is more sensitive, compared to stand alone venography, in identifying and quantifying iliofemoral vein obstructive lesions.<sup>38</sup>

### Technical Considerations

Deep venous procedures that involve iliofemoral stenting can have good outcomes with excellent patency, provided that they are done not only by interventionalists with appropriate expertise, but with appropriate resources too. Since these procedures are mostly done for non-life or limb threatening conditions, optimizing the outcomes is of paramount importance. Procedures can be done under local anesthesia and mild sedation or under general anesthesia. Stenting and ballooning of chronic occlusion may sometimes cause significant pain and discomfort and another important factor that needs to be taken into consideration is the anticipated length of the procedure. Some cases (e.g. chronic ilio caval occlusions) should be anticipated to last more than 2 hours.

Inferior vena cava filters, even when acute DVT is treated, are rarely needed.<sup>39</sup>

### Access

Ultrasound-guided access to the deep venous system is commonly performed through the ipsilateral femoral or deep femoral vein in the upper thigh or mid thigh. Some interven-

tionalists may choose jugular access, but this will require very long sheaths and catheters and access to the deep femoral or femoral veins may be cumbersome. For acute iliofemoral DVT that commonly extends to the femoropopliteal level, popliteal or tibial access (patient prone) will be required.

### Crossing the lesion

Traversing nonobstructive venous lesions is usually straightforward using standard techniques. In the setting of acute DVT, crossing through the thrombus is typically easy. Thrombolysis or suction thrombectomy will be required before evaluating the underlying lesion for stenting. There are various thrombolysis protocols, the detailed description of which goes beyond the scope of this article.<sup>5</sup>

Chronic total occlusions of the ilio caval system will require more advanced skills. Typically, a stiff or floppy hydrophilic guide wire with a straight or angled tip along with a supporting catheter will work through the trabeculations of the chronic thrombus. (Figure 3) The use of crossing sets (e.g. Tri-Force kit (Cook Medical, Bloomington, IN)) and even re-entry devices can be helpful in tight chronic lesions. Not infrequently, 0.035" catheters may be too large to cross tight lesions; 0.018" and even 0.014" systems may be used for crossing and predilating the lesions (4-6 mm balloons) before switching to an 0.035 platform for IVUS and stenting. Whenever perforation is suspected, the wire is withdrawn and re-advanced without the need for aborting the procedure because of the low venous pressures and the perivenous fibrosis.

After crossing the lesion and before initiating balloon venoplasty, IVUS is essential to decide the length of the lesion that will guide the length of the stent(s). If unavailable, venography using anteroposterior, 45° and 60° oblique projections are recommended to better delineate the stenosis.

### Stenting

Venous balloon angioplasty alone is a suboptimal intervention, and the lesion almost always recurs.<sup>10,23,24,27</sup> Cephalad landing zones include the IVC up to the level but not including the right atrium. Caudal landing zones include crossing the inguinal ligament down to the common femoral vein without jailing the deep femoral vein. Caval filters that may have been left behind for many years, are stented across to optimize outflow. (Figure 3) Some interventionalists may attempt a challenging retrieval opting to not displace the filter. This may prevent longer term unknown complications but comes at the cost of a much longer and higher risk procedure.

After traversing, predilating and evaluating (with IVUS) the lesion, the entire track is dilated using 14- to 18-mm high pressure balloons depending on the involved vein segment. The common femoral vein can accept up to a 14-mm, the external iliac vein a 16-mm, the common iliac an 18-mm and the IVC an 18- to 24-mm balloon. Subsequent stenting usually corresponds to the size of the balloon. In general, self-expanding stents are used and it is essential to postdilate the stents to allow full expansion. With regard to the extent of stenting, all lesions should be stented without leaving skip areas behind. As previously mentioned it is acceptable to stent below the inguinal ligament into the common femoral vein as stent fracture in the venous system is infrequently encountered. Patency is highly related to an unobstructed inflow to the stent.<sup>5</sup>

The ilio caval junction is another critical and common failure point that needs to be traversed and stented in iliac compression syndrome, otherwise stent compression and restenosis are to be expected; the radial force of the frequently used in U.S. Wallstent (Boston Scientific, Nantick, MA) is high at its main body and lower towards its edges. Extension of the stent into the vena cava to avoid this problem may render subsequent contralateral stenting technically difficult and possibly contribute to partial jailing of contralateral flow. Acute jailing of the contralateral iliac is less of a concern compared with chronic subclinical jailing. Stent extension into the IVC has raised concerns about contralateral limb outflow obstruction in a chronic fashion. The interstices of the venous stent covering the contralateral iliac become lined up with neointima that eventually occlude the outflow. Techniques to circumvent this occurrence have been proposed including using the Gianturco Z stent (Cook Medical, Bloomington, IN) that has wider interstices, or more recently dedicated open cell or oblique stents.<sup>27, 40-41</sup> The double-barrel technique works for bi-iliac stenting and is optimal whenever bilateral or ilio-caval disease is present. (Figure 3) Others prefer inverted Y techniques, deploying a single barrel inside the IVC and then extending the iliac stents into this.<sup>1, 27, 42, 43</sup> Re-assessing after stenting with IVUS is also advisable to ensure appropriate expansion and apposition.

### Anticoagulation and Stent Surveillance

The relative importance of antiplatelet agents versus anticoagulants has never been evaluated and is largely based on extrapolation from the arterial system and an understanding of the venous system. Without any hard evidence available, a reasonable antithrombotic plan is anticoagulation (DVT protocol using any approved agent) plus aspirin 81-100mg for 3 months and then aspirin (or clopidogrel) only. Chronic anticoagulation (DVT protocol using any approved agent) should be maintained for higher risk patients (e.g. thrombophilia, unprovoked DVT) and complex post-thrombotic ilio caval reconstructions. Venous stent surveillance aims at detecting stent thrombosis or restenosis. Duplex surveillance at 1 month, 3 months and yearly thereafter is a reasonable surveillance program. If a greater than 50% restenosis is identified balloon venoplasty is recommended to maintain patency regardless of symptoms.<sup>10, 23, 24, 44</sup>

### CONCLUSION

Venous iliofemoral and caval stenting are increasingly used as more evidence accumulates supporting the open vein hypothesis, the safety, efficacy, and durability of these interventions. The indications are still evolving, but there is little doubt that certain patients with iliofemoral venous occlusive disease, acute or chronic, can avoid or abolish pain, swelling and chronic non-healing ulcers to enjoy a better quality of life. Thoughtful patient selection and appropriate team expertise are critical components of a successful outcome.

### REFERENCES

- 1 Abou Ali AN, Avgerinos ED, Chaer RA. Role of venous stenting for iliofemoral and vena cava venous obstruction. *Clin North Amer* 2018;98:361-71
- 2 Razavi M, Jaff M, Miller LE. Effectiveness of stent placement for iliofemoral venous outflow obstruction. *Circ Cardiovasc Interv* 2015;8:e002772
- 3 Seager MJ, Busuttill A, Dharmarajah B, Davies AH. A systematic review of endovenous stenting for venous disease secondary to iliac vein obstruction. *Eur J Vasc Endovasc Surg* 2016;51:100-120
- 4 Hager ES, Yuo T, Tahara R, Dillavou E, Al-Khoury G, Marone L, et al. Outcomes of endovascular intervention for May-Thurner syndrome. *J Vasc Surg* 2013;1:270-275
- 5 Avgerinos ED, Saadeddin Z, Abou Ali AN, Pandya Y, Hager E, Singh M, et al. Outcomes and predictors of failure of iliac vein stenting following catheter directed thrombolysis for acute iliofemoral thrombosis. *J Vasc Surg Ven Lymph* 2019 in press
- 6 Raju S, Neglen P. High prevalence of nonthrombotic iliac vein lesions in chronic venous disease: a permissive role in pathogenicity. *J Vasc Surg* 2006;44:136-43
- 7 May R, Thurner J. The cause of the predominantly sinusoidal occurrence of thrombosis of the pelvic veins. *Angiology* 1957;8:419-427
- 8 Kibbe MR, Ujiki M, Goodwin AL, Eskandari M, Yao J, Matsumura J. Iliac vein compression in an asymptomatic patient population. *J Vasc Surg* 2004; 39:937-943.
- 9 Neglen P, Thrasher TL, Raju S. Venous outflow obstruction: an underestimated contributor to chronic venous disease. *J Vasc Surg* 2003;38:879-85.
- 10 Wittens C, Davies AH, Baekgaard N, et al. Management of chronic venous disease: clinical practice guidelines of the European Society for Vascular Surgery. *Eur J Vasc Endovasc Surg* 2015;49:678-737
- 11 Bashir R, Zack C, Zhao H, Comerota A, Bove A. Comparative Outcomes of Catheter-Directed Thrombolysis Plus Anticoagulation vs Anticoagulation Alone to Treat Lower-Extremity Proximal Deep Vein Thrombosis. *JAMA Intern Med.* 2014;174:1494.
- 12 Mewissen MW, Seabrook GR, Meissner MH, Cynamon J, Labropoulos N, Haughton SH. Catheter-directed thrombolysis for lower extremity deep venous thrombosis: report of a national multicenter registry. *Radiology* 1999;211:39-49.
- 13 Enden T, Haig Y, Klow NE, Slagsvold CE, Sandvik L, Ghanima W, et al. Long-term outcome after additional catheter-directed thrombolysis versus standard treatment for acute iliofemoral deep vein thrombosis (the CaVenT study): a randomised controlled trial. *Lancet* 2012;379:31-8.
- 14 Haig Y, Enden T, Grøtta O, Kløw N, Slagsvold C, Ghanima W, et al. Post-thrombotic syndrome after catheter-directed thrombolysis for deep vein thrombosis (CaVenT): 5-year follow-up results of an open-label, randomised controlled trial. *The Lancet Haematology.* 2016;3:e64-e71
- 15 Vedantham S. Catheter-directed thrombolysis to avoid late consequences of acute deep vein thrombosis. *Thromb Res.* 2018;164:125-128
- 16 Vedantham S, Goldhaber SZ, Julian JA, Kahn SR, Jaff MR, Cohen DJ et al. Pharmacomechanical catheter directed thrombolysis for deep-vein thrombosis. *N Engl J Med* 2017;377:2240-2252
- 17 Avgerinos ED, Chaer RA. The ATTRACTiveness of catheter directed thrombolysis. *J Vasc Surg Venous Lymphat Dis-*

- ord 2018;6:303
- 18 Aziz F, Comerota AJ. Quantity of residual thrombus after successful catheter-directed thrombolysis for iliofemoral deep venous thrombosis correlates with recurrence. *Eur J Vasc Endovasc Surg* 2012;44:210-3.
  - 19 Baekgaard N, Broholm R, Just S, Jorgensen M, Jensen LP. Long-term results using catheter-directed thrombolysis in 103 lower limbs with acute iliofemoral venous thrombosis. *Eur J Vasc Endovasc Surg* 2010;39:112-7.
  - 20 Protack CD, Bakken AM, Patel N, Saad WE, Waldman DL, Davies MG. Long-term outcomes of catheter directed thrombolysis for lower extremity deep venous thrombosis without prophylactic inferior vena cava filter placement. *J Vasc Surg* 2007;45:992-7; discussion 7.
  - 21 Lin PH, Zhou W, Dardik A, Mussa F, Kougias P, Hedayati N, et al. Catheter-direct thrombolysis versus pharmacomechanical thrombectomy for treatment of symptomatic lower extremity deep venous thrombosis. *Am J Surg* 2006;192:782-8.
  - 22 Xue G, Huang X, Ye M, Liang W, Zhang H, Zhang J, et al. Catheter-directed Thrombolysis and Stenting in the Treatment of Iliac Vein Compression Syndrome with Acute Iliofemoral Deep Vein Thrombosis: Outcome and Follow-up. *Ann Vasc Surg* 2014;28:957-963.
  - 23 Meissner MH, Gloviczki P, Comerota AJ, Dalsing MC, Eklof BG, Gillespie D L, et al. Early thrombus removal strategies for acute deep venous thrombosis: clinical practice guidelines of the Society for Vascular Surgery and the American Venous Forum. *J Vasc Surg* 2012;55:1449-62.
  - 24 Mahnken A, Thomson K, de Haan M, O'Sullivan G. CIRSE Standards of Practice Guidelines on Iliocaval Stenting. *Cardiovasc Intervent Radiol*. 2014;37(4):889-97
  - 25 Kahn SR. The post-thrombotic syndrome: the forgotten morbidity of deep venous thrombosis. *J Thromb Thrombolysis* 2006;21:41-8
  - 26 Raju S, Darcey R, Neglén P, Flowood J. Unexpected major role for venous stenting in deep reflux disease. *J Vasc Surg* 2010;51:401-8; discussion: 408.
  - 27 Raju S. Treatment of iliac-caval outflow obstruction. *Semin Vasc Surg* 2015;28:47-53.
  - 28 Eklof B, Rutherford RB, Bergan JJ, Carpentier PH, Gloviczki P, Kistner RL, et al. Revision of the CEAP classification for chronic venous disorders: Consensus statement. *Journal of Vascular Surgery* 2004;40:1248-1252.
  - 29 Vasquez MA, Rabe E, McLafferty RB, Shortell CK, Marston WA, Gillespie D, et al., American Venous Forum Ad Hoc Outcomes Working Group. Revision of the venous clinical severity score: Venous outcomes consensus statement: Special communication of the American Venous Forum Ad Hoc Outcomes Working Group. *Journal of Vascular Surgery*, 2010;52:1387-1396.
  - 30 Kahn SR. Measurement properties of the Villalta scale to define and classify the severity of the post-thrombotic syndrome. *J Thromb Haemost* 2009;7:884-888
  - 31 Labropoulos N, Borge M, Pierce K, Pappas PJ. Criteria for defining significant central vein stenosis with duplex ultrasound. *J Vasc Surg* 2007;46(1):101-7
  - 32 Gohel MS, Barwell JR, Taylor M, Chant T, Foy C, Earnshaw JJ, et al. Long term results of compression therapy alone versus compression plus surgery in chronic venous ulceration (ESCHAR): randomised controlled trial. *BMJ* 2007;335:83.
  - 33 Montminy ML, Jayaraj A, Raju S. A systematic review of the efficacy and limitations of venous intervention in stasis ulceration. *J Vasc Surg Venous Lymphat Disord* 2018;6:376-98
  - 34 Gohel MS, Heatley F, Liu X, et al. A randomized trial of early endovenous ablation in venous ulceration. *N Engl J Med* 2018;378(22):2105-2114
  - 35 Choi JW, Jae HJ, Kim HC, Min SI, Min SK, Lee W, Chung JW. CT venography for deep venous thrombosis: can it predict catheter-directed thrombolysis prognosis in patients with iliac vein compression syndrome? *Int J Cardiovasc Imaging* 2015;31(2):417-26
  - 36 Fraser DG, Moody AR, Martel A, Morgan PS. Re-evaluation of iliac compression syndrome using magnetic resonance imaging in patients with acute deep venous thromboses. *J Vasc Surg* 2004;40:604-611
  - 37 McDermott S, Oliveira G, Ergu I E, Brazeau N, Wicky S, Oklu R. May-Thurner syndrome: can it be diagnosed by a single MR venography study? *Diagn Interv Radiol* 2013;19:44-48
  - 38 Gagne PJ, Tahara R, Fastabend CP, et al. Venography versus intravascular ultrasound for diagnosing and treating iliofemoral vein obstruction. *J Vasc Surg Vein Lymph* 2017;5(5):678-687
  - 39 Avgerinos ED, Hager ES, Jeyabalan G, Marone L, et al. Inferior vena cava filter placement during thrombolysis for acute iliofemoral deep venous thrombosis. *J Vasc Surg Venous Lymphat Disord* 2014;2: 274-81
  - 40 Murphy EH, Johns B, Buck W, et al. Deep venous thrombosis associated with caval extension of iliac stents. *J Vasc Surg Venous Lymphat Disord* 2017;5(1):8-2017
  - 41 Stuck AK, Kunz S, Baumgardner I, et al. Patency and clinical outcomes of a dedicated self-expanding, hybrid oblique stent used in the treatment of common iliac vein compression. *J Endovasc Therapy* 2017;24:159-166
  - 42 Erben Y, Bjarnason H, Oladottir GL, et al. Endovascular recanalization for nonmalignant obstruction of the inferior vena cava. *J Vasc Surg Venous Lymphat* 2018;6:173-82
  - 43 Chick JFB, Srinivasa RN, Cooper KJ. Endovascular iliacaval reconstruction for chronic iliacaval thrombosis: the data, where we are, and how it is done. *Tech Vasc Interv Radiol* 2018;21:92-104
  - 44 Raju S, Tackett PJ, Neglen P. Reinterventions for nonocclusive iliofemoral venous stent malfunctions. *J Vasc Surg* 2009;49:511-8.