

## A symptomatic popliteal venous aneurysm: A case report

Eleni Tsamantioti<sup>1</sup>, Chrysanthi P. Papageorgopoulou<sup>2</sup>, Stavros Kakkos<sup>2</sup>

<sup>1</sup>Medical School, University of Patras, Patras, Greece

<sup>2</sup>Department of Vascular Surgery, University Hospital of Patras, Patras, Greece

### Abstract:

Primary popliteal venous aneurysm (PVA) is a rare condition, with less than 200 cases being reported in the literature. While many patients remain asymptomatic, the majority of them are diagnosed during workup for the venous thromboembolic complications they cause. Due to the high risk of primary or recurrent deep vein thrombosis and pulmonary embolism associated with PVAs, surgical management is usually recommended. We present a case of symptomatic PVA, identified on ultrasound, in a 39-year-old male patient who presented with right leg varicose veins. Natural history studies on PVAs are scarce and expedited repair may be warranted in patients with high risk features for thrombosis like our patient.

### INTRODUCTION

Popliteal venous aneurysm (PVA) is a rare vascular disorder, with approximately 200 reported cases in the literature<sup>1</sup>. Venous aneurysm is defined as a persisted isolated dilatation of twice the normal vein diameter<sup>3</sup>. The average diameter of a normal popliteal vein is between 6mm to 8 mm.<sup>4</sup> Popliteal venous aneurysms are the second most common type of venous aneurysms following the internal jugular vein. While many patients remain asymptomatic, the majority of them are diagnosed on workup for the venous thromboembolic complications they cause. Diagnosis can be confirmed by colour duplex ultrasound scanning and computed tomographic venography (CTV) or rarely digital venography<sup>2</sup>. Colour duplex ultrasound scanning has the advantage that it can depict not only the morphology but also blood flow disturbances, such as turbulent and retrograde flow in the aneurysmal segments. The flow information provided by this method, allows a risk assessment of possible thrombus formation in popliteal vein aneurysms. The pathogenesis of PVA remains unclear. PVAs are associated with high risk of deep venous thrombosis (DVT) and pulmonary embolism (PE). The risk for a PE is unforeseeable if the aneurysm diameter is larger than 20mm even with anticoagulant therapy, so surgical treatment is recommended<sup>1</sup>. We present a rare case of a PVA in a patient with history of superficial vein thrombosis and signs of venous stasis who developed PVA thrombosis while awaiting repair.

### CASE PRESENTATION

A 39-year-old obese man with a past medical history of right leg tremor, presented to the outpatient clinic of our department with symptomatic varicose veins due to great saphenous vein insufficiency of the right lower extremity. He reported two episodes of superficial vein thrombosis of his right leg varicosities some six months ago, treated with a low molecular weight heparin. On preoperative mapping of the right great saphenous vein with Duplex scanning, while checking the small saphenous vein a PVA was incidentally diagnosed, which measured approximately 2.24 x 1.95 cm with signs of venous stasis (donaut sign, Fig.1).

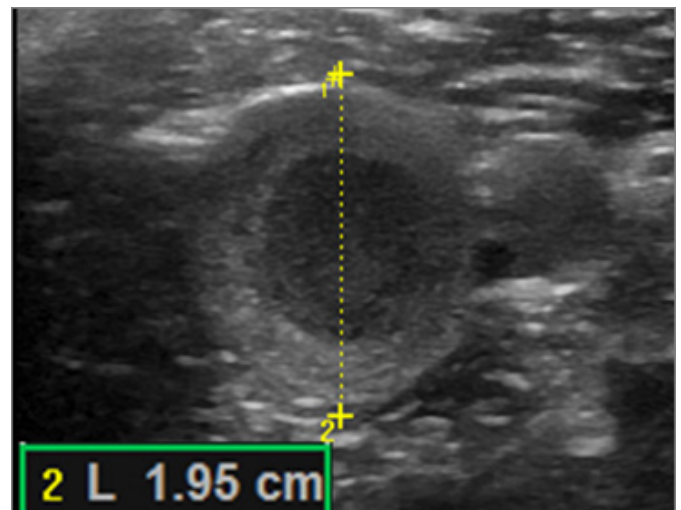


Figure 1. Duplex ultrasound scanning: donaut sign

Following an uncomplicated elective saphenectomy and varicose vein avulsion procedure he was investigated further with magnetic resonance venography, which confirmed the diagnosis of a focal PVA. Three months after the saphenectomy procedure, while awaiting repair of the PVA, our patient

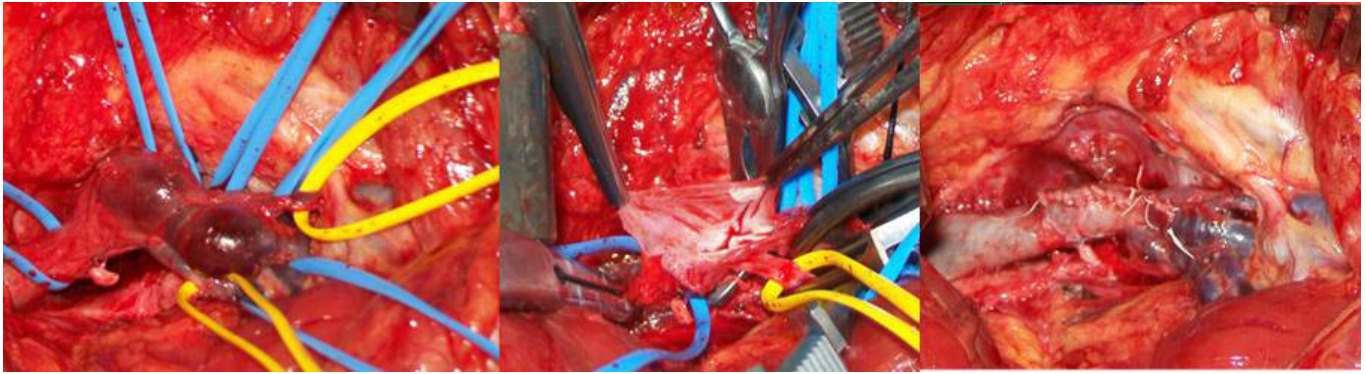
Author for correspondence:

**Stavros Kakkos**

Department of Vascular Surgery,  
University Hospital of Patras, Rio, 26504, Greece

E-mail: kakkos@upatras.gr

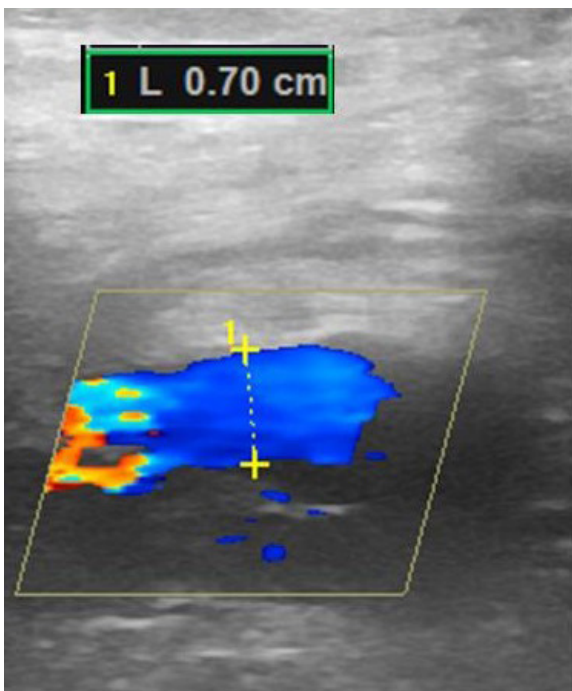
ISSN 1106-7237/ 2019 Hellenic Society of Vascular and Endovascular Surgery Published by Rotonda Publications  
All rights reserved. <https://www.heljves.com>



**Figure 2.** Tangential aneurysmectomy and lateral venorrhaphy of the popliteal venous aneurysm of our patient

developed pain in the right popliteal fossa and was diagnosed as having partial thrombosis of the PVA on Duplex. He was treated initially with tinzaparin 16,000 iu OD subcutaneously switched to apixaban 5mg BID for a total of three months. In order to prevent a recurrent thromboembolic event, after complete resolution of the PVA thrombus on Duplex, we repaired the PVA with tangential aneurysmectomy and lateral venorrhaphy (Fig. 2).

Postoperative course was uneventful, and he was discharged on the second postoperative day on enoxaparin 80mg BID switched to apixaban 5mg BID for a month. At six months postoperatively our patient remains asymptomatic, the reconstruction remains patent on color Duplex with no early or late recurrence of thromboembolic events being reported so far. (Fig. 3)



**Figure 3.** Patency of reconstruction in color Duplex scan during 6-month follow up

## DISCUSSION

Aneurysmal dilatation of the popliteal vein is very rare vascular disorder<sup>1</sup>. PVAs are usually left sided and can occur in both sexes with predominance in females. Additionally, PVAs have been presented in a wide range of ages. The youngest case reported is a 12 year-old girl with Klippel-Trenaunay syndrome and with a massive PE probably caused by PVA<sup>4</sup>. Due to the fact that PVA can affect both children and adults, a theory has been developed that the dilatation develops progressively in a substrate of damaged, weakened vascular wall.

The etiology of the PVA remains unclear and has been correlated with congenital vascular abnormalities, venous hypertension, traumatic, inflammatory and localized-degenerative conditions<sup>5</sup>. However, the most plausible explanation for their formation is that they are multifactorial; a combination of congenital malformation and mechanical injury. Furthermore, giant PVAs have been observed in Parkes-Weber syndrome, a congenital vascular abnormality defined by limb overgrowth, macro arteriovenous fistula, and capillary-venous deformity<sup>6</sup>. PVAs can be asymptomatic and identified incidentally during the diagnostic approach of venous insufficiency or can present with localized symptoms like swelling or pain<sup>5</sup>. Most of the times, they become clinically obvious causing PE or DVT, conditions with a high rate of morbidity and mortality. In addition, patients with recurrent PE should always be screened for PVA, since the source of emboli is often the aneurysm<sup>1</sup>.

Several imaging techniques can be used for the diagnosis of PVA. The initial imaging examination is colour duplex ultrasound scanning, which is sensitive, non invasive and gives the ability to dynamically assess blood flow. In the past, the gold standard imaging technique was venography, which although being more accurate has nowadays been replaced by colour duplex ultrasound scan<sup>8</sup>. The types of venography that are being used for the diagnosis of a PVA are computed tomography venography, magnetic resonance venography and invasive digital venography<sup>2</sup>.

There is no consensus on which popliteal aneurysms to treat. In asymptomatic cases, with aneurysm diameter less than 20mm, the preferred treatment options are mostly sur-

veillance, anticoagulation or surgery.<sup>9</sup>

It has been shown that the incidence of DVT is directly related to the size of the aneurysm. Hence, patients with aneurysm larger than 20mm with or without thrombus should either be treated surgically or receive lifelong anticoagulation therapy<sup>9</sup>. Furthermore, patients with asymptomatic saccular aneurysm, regardless of its diameter, should be treated surgically. The treatment options include:

1. Tangential aneurysmectomy and lateral venorrhaphy, followed by low complications if the anatomy permits.
2. Resection of the aneurysm and direct end-to-end anastomosis of the popliteal vein or replacement with a vein graft.<sup>10</sup>

Both of them are performed from the posterior approach, with the patient being placed in prone position. The postoperative treatment consists of anticoagulation therapy for a short period of time and compression stockings of 20 to 30mmHg up to the thigh for three months. The use of vein grafts can be complicated with thrombosis of the vein graft or haematoma, requiring further treatment. Hence, tangential aneurysmectomy and lateral venorrhaphy is the preferable surgical treatment, due to fewer complications.<sup>10</sup>

## CONCLUSION

We present a rare case of a PVA in a patient with history of superficial vein thrombosis and signs of venous stasis who developed PVA thrombosis while awaiting repair. Natural history studies on PVAs are scarce and expedited repair may be warranted in patients with high risk features for thrombosis like our patient.

*Acknowledgements: None*

## REFERENCES

- 1 Lim J, Marshall M. Popliteal vein aneurysm presenting as recurrent pulmonary embolism. *J Radiol Case Rep.* 2015;9(4):23-27. doi:10.3941/jrcr.v9i4.2509
- 2 Teter KA, Maldonado TM, Adelman MA. A systematic review of venous aneurysms by anatomic location. *J Vasc surgery Venous Lymphat Disord.* 2018;6(3):408-413. doi:10.1016/j.jvsv.2017.11.014
- 3 McDevitt DT, Lohr JM, Martin KD, Welling RE, Sampson MG. Bilateral popliteal vein aneurysms. *Ann Vasc Surg.* 1993;7(3):282-286. doi:10.1007/BF02000255
- 4 Sessa C, Nicolini P, Perrin M, Farah I, Magne JL, Guidicelli H. Management of symptomatic and asymptomatic popliteal venous aneurysms: a retrospective analysis of 25 patients and review of the literature. *J Vasc Surg.* 2000;32(5):902-912. doi:10.1067/mva.2000.110353
- 5 Sandstrom A, Reynolds A, Jha P. Popliteal Vein Aneurysm: A Rare Cause of Pulmonary Emboli. *Ann Vasc Surg.* 2017;38:315.e15-315.e17. doi:10.1016/j.avsg.2016.05.093
- 6 Cury MVM, Issa AAT. Giant popliteal vein aneurysm in Parkes-Weber syndrome. *Surgery.* 2018;163(4):963-964. doi:10.1016/j.surg.2017.10.002
- 7 Tsolakis JA, Kakkos SK, Panagiotopoulos E. Popliteal venous aneurysm mimicking a soft tissue tumour. A case report. *Int Angiol.* 1999;18(1):74-76. <http://www.ncbi.nlm.nih.gov/pubmed/10392485>. Accessed March 19, 2019.
- 8 Ghali MGZ, Taylor JA, Mallon M, et al. Popliteal Venous Aneurysm Presenting With Bilateral Pulmonary Thromboembolism. *Vasc Endovascular Surg.* 2018;52(4):287-290. doi:10.1177/1538574417754031
- 9 Noppeney T, Kopp R, Pfister K, Schierling W, Noppeney J, Cucuruz B. Treatment of popliteal vein aneurysms. *J Vasc Surg Venous Lymphat Disord.* March 2019. doi:10.1016/j.jvsv.2018.12.013
- 10 Johnstone JK, Fleming MD, Gloviczki P, et al. Surgical treatment of popliteal venous aneurysms. *Ann Vasc Surg.* 2015;29(6):1084-1089. doi:10.1016/j.avsg.2015.02.009