Endovascular aneurysm repair in the presence of a horseshoe kidney with preservation of the accessory renal artery

Petroula Nana[1], George Kouvelos[1], Metaxia Mpareka[2], Eleni Arnaoutoglou[2], Miltiadis Matsagkas[1]

[1]Department of Vascular Surgery, Faculty of Medicine, School of Health Sciences, University of Thessaly, Larissa, Greece
[2]Department of Anesthesiology, Faculty of Medicine, School of Health Sciences, University of Thessaly, Larissa, Greece

Abstract:

The incidence of a synchronous abdominal aortic aneurysm (AAA) and a horseshoe kidney is estimated at 0.12%. The horseshoe kidney is the commonest renal congenital anomaly. The application of the endovascular or open approach should aim to the preservation of accessory renal arteries >3mm and isthmus. We present a 56 year old male patient, with a co-existing horseshoe kidney and an infra-renal AAA. An accessory renal artery of 5mm in diameter was raising form the anterior aneurysmal sac and supplied with blood the large renal isthmus. A custom made device with an inner branch was used for aneurysm exclusion and accessory renal artery preservation. The patient was discharged the 4th post-operative day and the post-operative early follow-up was uneventful with aneurysm sac exclusion and adequate perfusion of the kidney isthmus through the patent inner branch.

INTRODUCTION

The incidence of a synchronous abdominal aortic aneurysm (AAA) and a horseshoe kidney is estimated at 0.12%.[1] The horseshoe kidney is the commonest renal anomaly which may be implicated with vascular anatomic variations.[1] Open surgical repair in these cases is demanding as the renal isthmus overlies at the anterior aneurysmal sac while arterial feeding of the isthmus directly from the aneurysmal sac may further complicate this aproach.[2,3] In current guidelines and literature, the preservation of accessory renal arteries of more than 3 mm in diameter or which supply more than 30% of renal parenchyma is recommended during aneurysm repair with endovascular means or open repair.[1,2,4] Endovascular management of patients with horseshoe kidney and concomitant infra-renal aneurysm is feasible.[5] However, the majority of cases present the application of standard EVAR with accessory renal artery coverage which is associated to the presentation of renal infarct and transient renal injury.[6] The application of branched devices may be feasible, although these grafts are not always readily available.[5] Herein, we report a case of a 56-year-old male, with a synchronous AAA and horseshoe kidney, treated endovascular with a custom-made device.

Author for correspondence:

Miltiadis Matsagkas

Professor of Vascular Surgery, Department of Vascular Surgery, Faculty of Medicine, School of Health Sciences, University of Thessaly, Mezourlo, 41110, Larissa, Greece

Tel: +30 2413 50 1739
E-mail: milmats@gmail.com

ISSN 2732-7175 / 2021 Hellenic Society of Vascular and Endovascular Surgery Published by Rotonda Publications
All rights reserved. https://www.heljves.com

CASE REPORT

A 56-year-old male, with a medical history of tobacco use, hypertension, dyslipidemia, and coronary artery disease (acute coronary syndrome 7 months ago, treated with coronary stent implantation and under dual antiplatelet syndrome), presented to the outpatient clinic due to an infra-renal AAA. Computed tomography angiography (CTA) revealed the presence of a 53mm aneurysm and a horseshoe kidney, overlying the anterior aortic wall (Figure 1). A more precise evaluation of the CTA depicted an accessory renal artery of 5mm arising from the anterior sac wall and providing blood supply to the large renal isthmus (Figure 2). Considering the complex anatomy, the need to preserve the accessory renal artery due to its diameter and the patient's general status and consent, an endovascular approach, using a custom-made device with an inner branch, was decided to achieve sac exclusion and also retain the blood supply to the isthmus of the kidney. After careful sizing (Figure 3 & 4) and planning of the aneurysm itself, as well as of the accessory renal artery was made, a bifurcated aortic graft having an inner branch for the accessory renal artery was ordered (Figure 5).

Access was achieved using both femoral arteries (cut down access) and the left brachial artery (percutaneous access). Initially, the main body of the device (28x125mm, Jotec, Cryolife, DE) was deployed right distal to the left renal artery (lowest). Subsequently, antegrade catheterization of the inner branch via the left brachial artery was undertaken using a vertebral catheter and a hydrophilic 0.035'' wire. The catheterization of the accessory artery followed using the same materials and a 7th Fr hydrophilic sheath was advanced into the artery. At that point, due to a mild extravasation of contrast at a small branch of the accessory renal artery due to wire manipulations, an embolization was undertaken with 3x3.3mm micro-coils (Interlock, Boston Medical, USA), using a microcatheter. An angiography con-

firmed the elimination of the extravasation and subsequently, a balloon expandable covered stent (Be-Graft, 7x57mm) was inserted and successfully deployed to bridge the inner branch and the accessory renal artery. Finally, the iliac limbs of the device were deployed to achieve distal sealing. The completion angiography showed no endoleak or hemorrhage of the renal branch while the stent-graft remained patent. The operation duration was 120 min and the contrast used was 80ml.

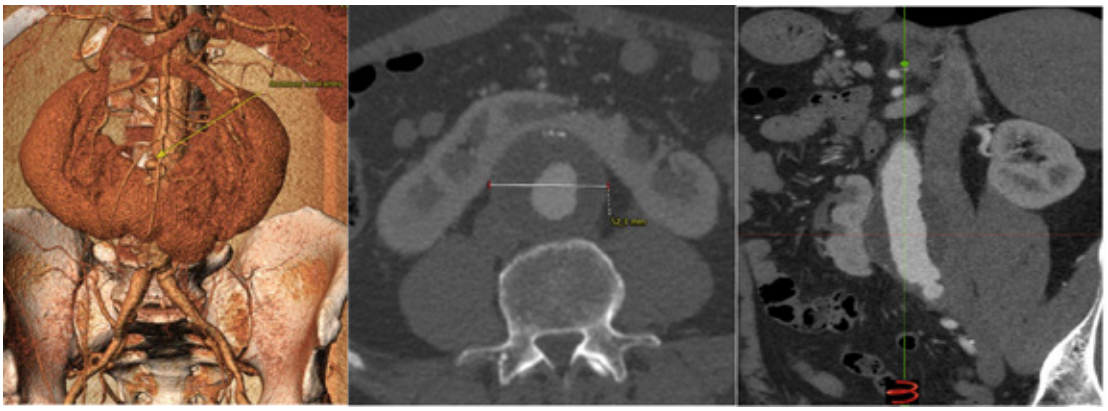

Figure 1. In Panel A, the horseshoe kidney overlying on the anterior wall of the aneurysm is depicted. Aneurysm diameter was 53mm while in panel B (axial view) and C (sagittal view), the large volume of the isthmus parenchyma is revealed.

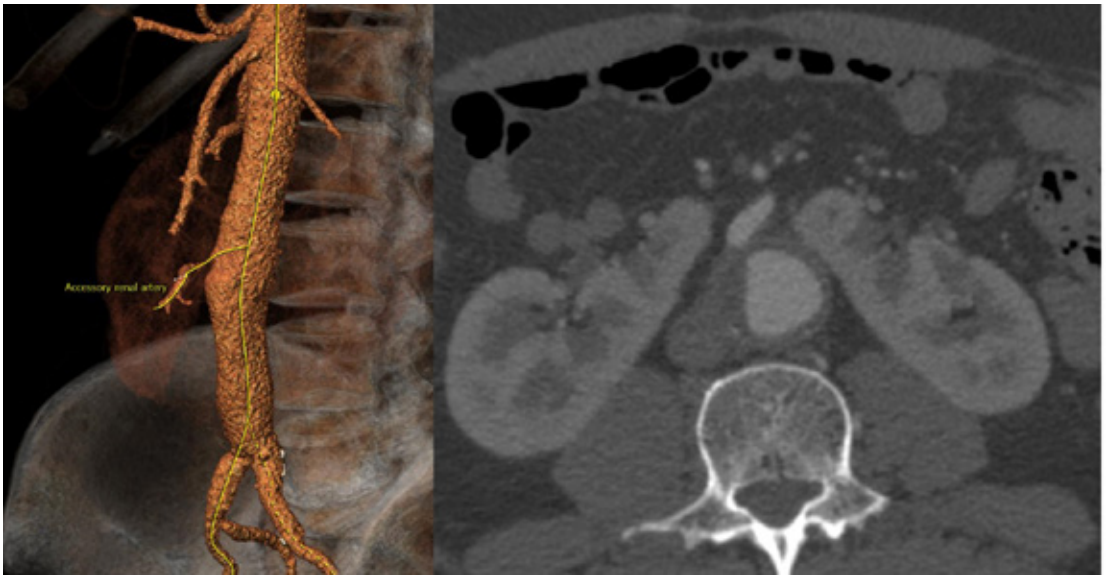

Figure 2. The accessory renal artery was originating from the anterior wall of the aneurysm. In panel A, the 3D reconstruction of the aneurysm depicts renal artery root and sharp angle origin while in panel B, an axial view of the artery reveals its large diameter.

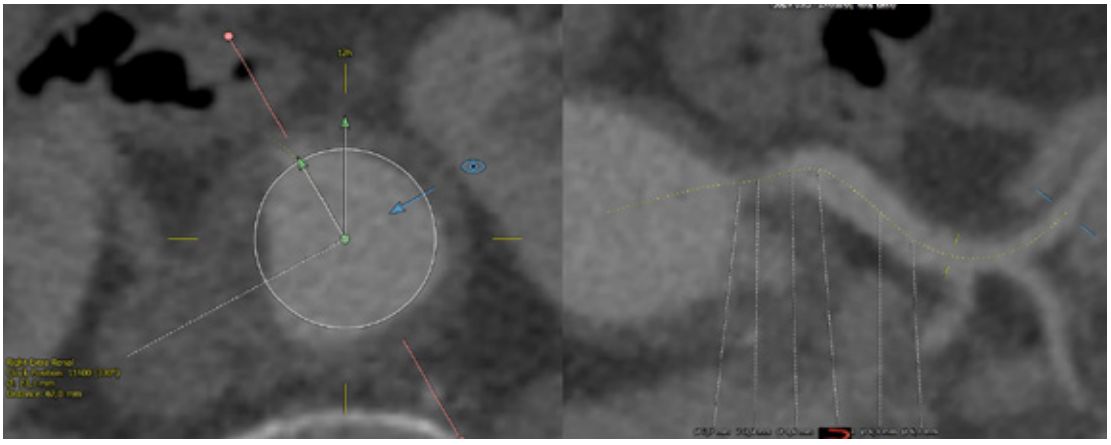

Figure 3. The pre-operative planning is mandatory in cases scheduled to be treated with custom made devices. The clockwise position of the accessory artery is presented in panel A while the center lumen line in panel B.

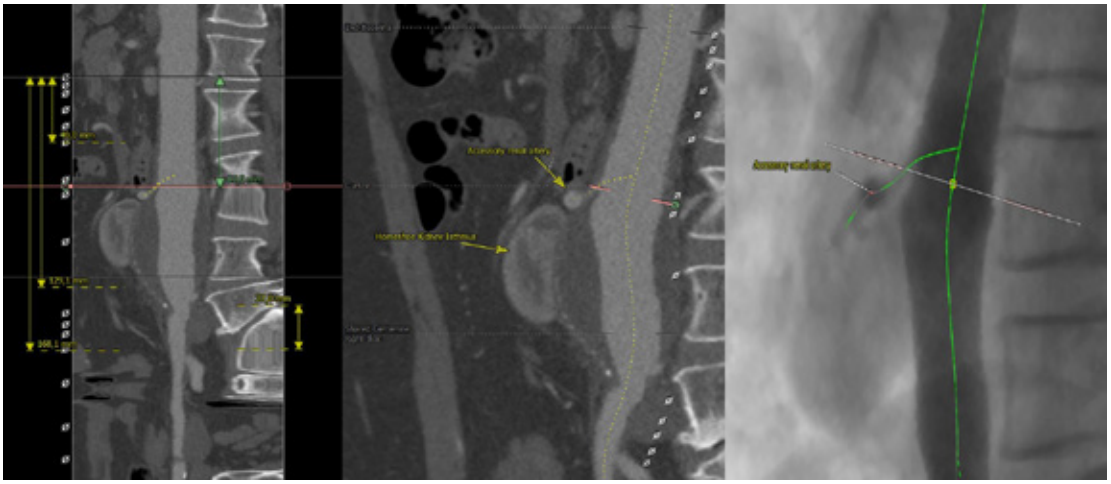

Figure 4. Aneurysm measurements are depicted in panel A while in panel B, a sagittal view of the center lumen line of the aneurysm and accessory artery is presented. In panel C, the pre-operative estimation of the C-ARM position for the most adequate renal angiography is presented.

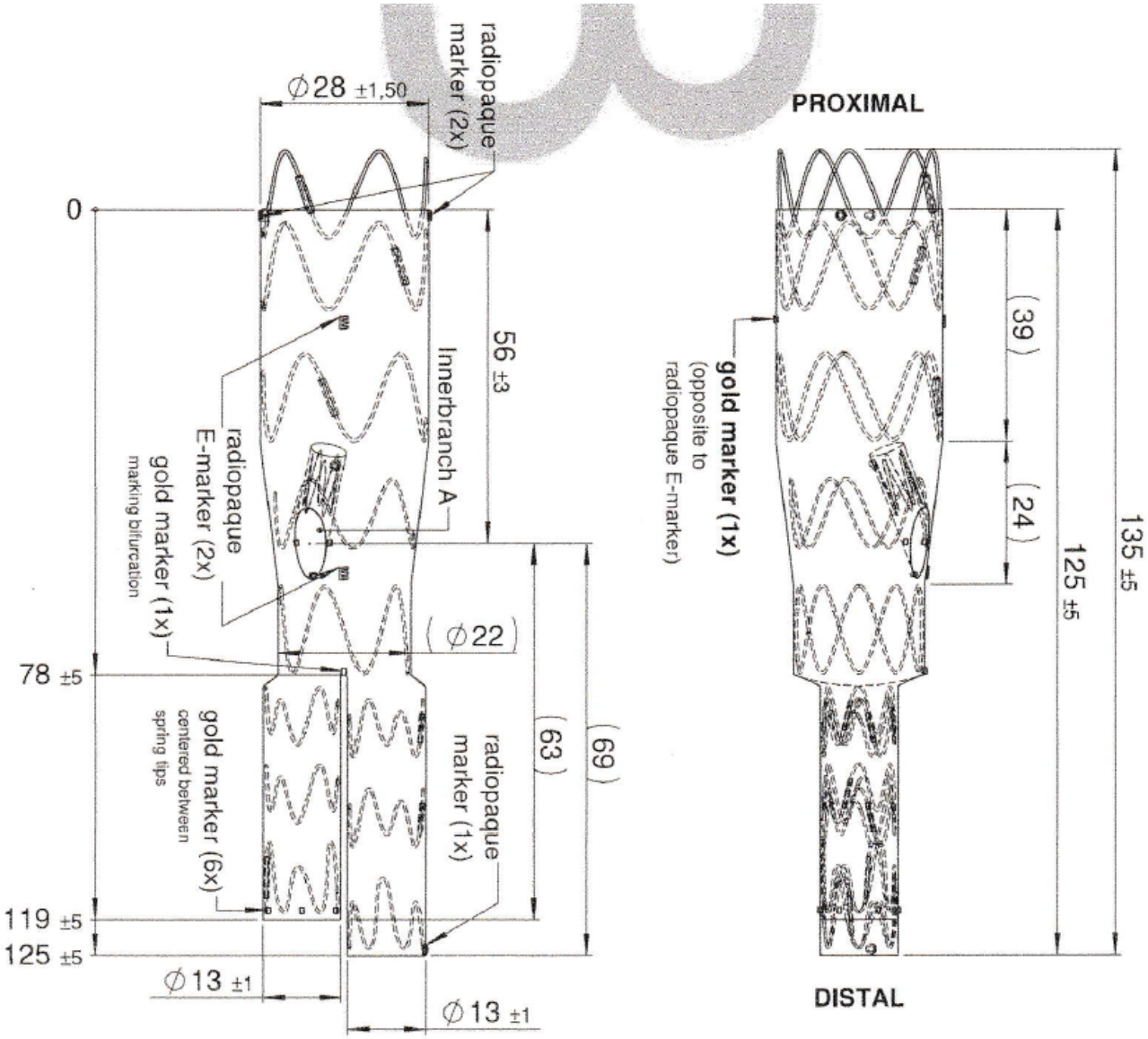

Figure 5. A custom-made device was decided to be used in this patient's management. The pre-operative schematic presentation of the endograft and the position of the inner branch are depicted.

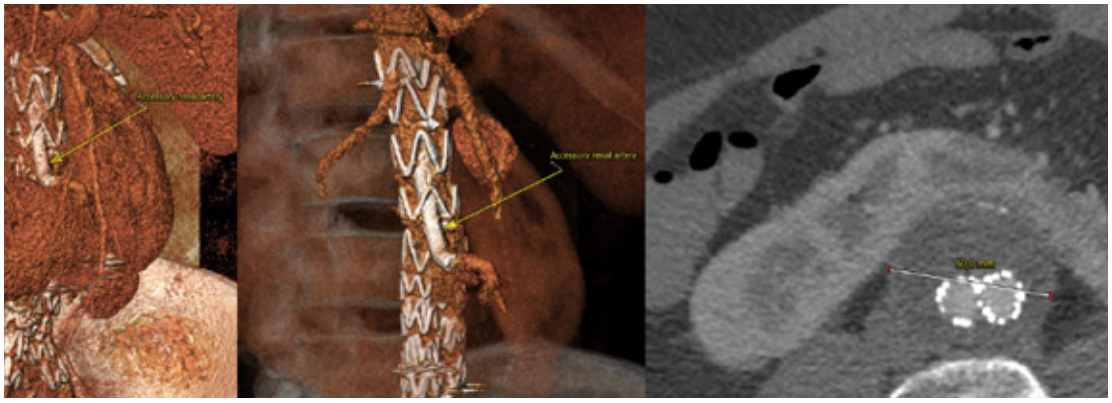

Figure 6. The post-operative CTA confirmed renal graft patency (yellow arrow in panel A & B). No renal infarct was detected (panel B). Aneurysm exclusion, no endoleak and sac shrinkage are depicted in axial view in panel C.

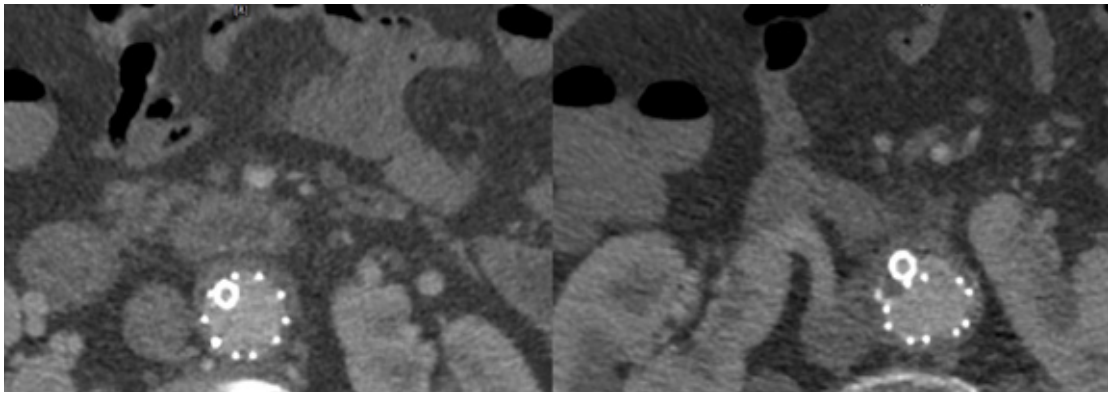

Figure 7. In panel A, the inner branch is presented while in panel B, the extra-graft location of the branch is depicted. Stent patency was revealed.

Pre-discharge CTA revealed no endoleak, branch and accessory renal artery patency and adequate aneurysm sealing (Figure 6 & 7). The patient was discharged the 4th post-operative day without any complication recorded and a normal renal function. He was advised to continue on double antiplatelet treatment for at least 3 months. First-month follow-up was uneventful while imaging with duplex ultrasonography depicted no aneurysm-related complication and a well perfused accessory renal artery.

DISCUSSION

Current guidelines recommend the preservation of accessory renal arteries when their diameter exceeds 3mm or if they offer blood supply to more than 30% of the renal parenchyma (Level of Evidence IIb B).[1] The exclusion of those supplementary arteries, when standard EVAR is applied, is not associated to endoleak or permanent renal impairment during follow-up, according to the literature.[1, 6] Regarding the co-existence of a horseshoe kidney and AAA, the recommendations propose as the preferred options, a retroperitoneal approach when an open repair is decided or an endovascular repair if anatomically feasible (Level of Evidence IIb C).[1] In the majority of endovascular cases in the literature, an accessory renal artery exclusion was decided; however, branched devices and parallel graft technique, when the artery arises from the aneurysmal sac have been also reported.[6] In open repair, artery re-implantation may be needed.[5] In any case, when the preservation of the accessory artery is needed, open or endovascular repair become more demanding procedures. In the case presented, the diameter of the accessory renal artery (5mm), as well as the large isthmus of the horseshoe kidney, made mandatory to preserve this artery. Given the cardiac condition of the patient because of the acute coronary syndrome 7 months ago, the need to remain under dual antiplatelet therapy, and his unwillingness for open surgery, a decision for endovascular repair was made, using a custom made graft having an inner branch for the accessory renal artery.

A complex renal vasculature is one of the main factors that makes a standard approach difficult, open or endovascular, in patients with horseshoe kidney.[4, 6] Open repair requires high surgical experience, as kidney tissue dissection and accessory renal artery re-implantation may be demanding.[6] As endovascular management expands its indications in aneurysmal disease, careful preoperative planning remains mandatory, especially in these complex cases.[6] In a retrospective case series published by Fabiani *et al.*, endovascular management of patients with infra-renal aneurysm and horseshoe kidney is safe and feasible, using standard EVAR. Accessory renal artery coverage was not associated to endoleaks or renal failure, as main renal arteries were preserved in all patients. In the long-term follow-up, no aneurysm-related death or renal complication was recorded.[5] However, in the current case report, the

large renal artery diameter would not permit a safe occlusion, as the possibility of a type II endoleak, renal infarct and chronic renal failure could not be precluded.

Different endovascular techniques may be applied in cases with atypical renal anatomy.[7] Fenestrated custom-made devices may offer a high patency rate of these renal branches, but the distance from the orifice of the accessory renal artery may be an issue as long covered stents are needed. Long-term outcomes are acceptable with no aneurysm related deaths, reinterventions, or renal function decrease so far.[7,8,9] Furthermore, other endovascular means, as the parallel graft technique (chimney) may be applied in patients with concomitant AAA and horseshoe kidney, showing encouraging results during the early follow-up.[10, 11] In this case the use of a custom made fenestration device was not preferred because of the stenosis and the sharp angulation of accessory renal artery at its origin. The use of the parallel graft technique was aborded because of the need of a very long covered stent and the risk of a late occlusion in a relatively young patient. Thus, we decided to procced with a custom made branched device, preferring an inner branch configuration at this point due to the quite restricted aortic diameter at the level of the accessory renal artery. In any case, detailed pre-operative CTA evaluation and planning, as well as an adequate endovascular experience are highly demanded in cases with synchronous AAA and horseshoe kidney, when the need to preserve an additional renal artery cannot be slide over.

CONCLUSION

The progression of the endovascular techniques and materials, such as custom-made devices may offer safe and feasible management in case of co-existence of a horseshoe kidney and an AAA, when the accessory renal artery is not to be sacrificed.

Acknowledgement: None

Conflict of interest: None

REFERENCES

1 Wanhainen A, Verzini F, Van Herzeele I, Allaire E, Bown M, Cohnert T, et al. Editor's Choice - European Society for Vascular Surgery (ESVS) 2019 Clinical Practice Guidelines on the Management of Abdominal Aorto-iliac Artery Aneurysms. Eur J Vasc Endovasc Surg. 2019;57:8-93.

2 Davidovic LB, Markovic M, Kostic D, Zlatanovic P, Mutavdzic P, Cvetic V. Open repair of ruptured abdominal aortic aneurysm with associated horseshoe kidney. Int Angiol. 2018;37:471-8.

3 Davidović L, Marković M, Ilic N, Koncar I, Kostić D, Simić D, et al. Repair of abdominal aortic aneurysms in the presence of the horseshoe kidney. Int Angiol. 2011;30:534-40.

4 Xanthopoulos D, Kouvelos G, Mitsis M, Papas N, Papadopoulos G, Matsagkas M. Abdominal aortic aneurysm and horseshoe kidney. A case report. Hellenic Vascular Surgery. 2010; 19:19-24.

5 Fabiani MA, González-Urquijo M, Riambau V, Puerta CV, Arochena NJM, Frolov SV, et al. EVAR Approach for Abdominal Aortic Aneurysm with Horseshoe Kidney: A Multicenter Experience. Ann Vasc Surg. 2019;58:232-7.

6 Sachsamanis G, Charisis N, Maltezos K, Galyfos G, Papapetrou A, Tsiliggiris V, et al. Management and therapeutic options for abdominal aortic aneurysm coexistent with horseshoe kidney. J Vasc Surg. 2019;69:1257-67.

7 Edwards JB, Wooster MD, Tanious A, Back MR. Management of Aortoiliac Aneurysms with Atypical Renal Artery Anatomy. Ann Vasc Surg. 2019;54:110-7.

8 Tenorio ER, Kärkkäinen JM, Marcondes GB, Lima GBB, Mendes BC, DeMartino RR, et al. Impact of intentional accessory renal artery coverage on renal outcomes after fenestrated-branched endovascular aortic repair. J Vasc Surg. 2020:S0741-5214(20)31695-5.

9 Chan YC, Qing KX, Cheng SW. Custom-made fenestrated stent grafts to preserve accessory renal arteries in patients with abdominal aortic aneurysms. Acta Chir Belg. 2014;114:183-8.

10 Boyacıoğlu K, Ketenciler S. Endovascular stent graft repair with chimney technique of an abdominal aortic aneurysm with concomitant horseshoe kidney. Turk Gogus Kalp Damar Cerrahisi Derg. 2020;28:377-81.

11 Sharma K, Babrowski T, Milner R. A Novel Chimney Approach for Management of Horseshoe Kidney During EVAR. EJVES Short Rep. 2016;33:16-9.